Sahel Journal of Life Sciences FUDMA (SAJOLS)
September 2025 Vol. 3(3): 362-370
ISSN: 3027-0456 (Print)
ISSN: 1595-5915 (Online)
DOI: *https://doi.org/10.33003/sajols-2025-0303-47*

Research Article

Outbreak of Newcastle Disease Complicated by Secondary Bacterial Infections in a Flock of 9-Week-Old Cockerels: A Case Report

Hussaini Usman DURKWA[1,6], *Jallailudeen Rabana LAWAL[2,6], Sanni Abdul BARKA[3,6], Arhyel Gana BALAMI[2,6], Oludotun Olubusola OLADELE [4,6], Ibrahim Waziri MUSA[5,6], and Dauda Luka MOHZO[7]

[1]Veterinary Teaching Hospital, Faculty of Veterinary Medicine, University of Jos, P.M.B. 2084, Jos, Plateau State, Nigeria
[2]Department of Veterinary Medicine, Faculty of Veterinary Medicine, University of Maiduguri, P.M.B. 1069, Maiduguri, Borno State, Nigeria
[3]Livestock Department, Agricultural Research Council of Nigeria, Plot 223D Cadastral Zone B6, Mabushi, Abuja, Nigeria
[4]Department of Veterinary Medicine, Faculty of Veterinary Medicine, University of Jos, P.M.B. 2084, Jos, Plateau State, Nigeria
[5]Department of Veterinary Medicine, Faculty of Veterinary Medicine, Ahmadu Bello University, P.M.B. 1045, Zaria, Kaduna State, Nigeria
[6]Postgraduate College of Veterinary Surgeon, Nigeria
[7]Department of Veterinary Pathology, Faculty of Veterinary Medicine, University of Maiduguri, P.M.B. 1069, Maiduguri, Borno State, Nigeria
***Corresponding Author's email*: rabana4real@unimaid.edu.ng**

ABSTRACT

Newcastle Disease (ND) is a highly contagious viral infection affecting all poultry species, causing significant economic losses globally. This report describes an outbreak of ND in a flock of 930 nine-week-old cockerels reared under a deep litter system in Maiduguri, Borno State, Nigeria. The outbreak was characterized by high morbidity and mortality despite prior vaccination with the LaSota strain. Affected birds exhibited severe diarrhea, anorexia, weakness, and respiratory distress. Six dead and three moribund birds were presented to the Poultry Unit of the Senator Ali Modu Sheriff Ultra-Modern Veterinary Hospital for investigation. Post-mortem examination revealed classical lesions consistent with velogenic viscerotropic ND, including tracheal and intestinal hemorrhages, cyanosis of the comb, and hepatic necrosis. Laboratory confirmation was achieved through Hemagglutination Inhibition (HI) and Enzyme-Linked Immunosorbent Assay (ELISA), which identified Newcastle Disease Virus (NDV) as the causative agent. Management interventions included antimicrobial therapy (Doxy-Gen 20/20) to combat secondary bacterial infections, electrolyte and energy supplementation (Vitalyte + Dextrose), immune modulation with Nigella sativa, and stringent biosecurity measures. This case emphasizes the need for enhanced vaccination strategies and strict biosecurity enforcement. This report stresses the significance of ND outbreaks in poultry production systems and the necessity for proactive disease surveillance and control measures. Timely diagnosis and coordinated response remain essential to mitigate the recurrent economic and health impact of ND in poultry production systems.

Keywords: Clinical Presentation; Cockerels; Newcastle Disease; Outbreak Management; Velogenic Viscerotropic NDV

Citation: Durkwa, H.U., Lawal, J.R., Barka, S.A., Balami, A.G., Oladele, O.O., Musa, I.W., & Mohzo, D.L. (2025). Outbreak of Newcastle Disease Complicated by Secondary Bacterial Infections in a Flock of 9-Week-Old Cockerels: A Case Report. *Sahel Journal of Life Sciences FUDMA*, 3(3): 362-370. DOI: *https://doi.org/10.33003/sajols-2025-0303-47*

INTRODUCTION

Newcastle disease (ND) is a highly contagious and economically important viral infection of domestic and wild avian species worldwide and can occasionally cause conjunctivitis in humans (Al-Rasheed, 2024). The disease is caused by Newcastle disease virus (NDV), a single-stranded, negative-sense RNA virus classified under the genus *Orthoavulavirus* in the family *Paramyxoviridae* (Jeong *et al*., 2018; WOAH, 2022). Highly virulent strains of NDV are listed by the World Organization for Animal Health (WOAH) as notifiable pathogens due to their severe impact on poultry production and trade (WOAH, 2022).

ND remains a persistent constraint on poultry productivity, especially in developing regions where lapses in biosecurity, poor vaccination compliance, and high bird density favor viral circulation (Hu *et al*., 2022). The virus exhibits varying virulence levels—velogenic, mesogenic, and lentogenic—with velogenic strains causing severe respiratory, gastrointestinal, and nervous signs accompanied by high mortality and economic losses (Nagy *et al*., 2020; Desingu *et al*., 2021; Kalonda *et al*., 2024). The clinical presentation and severity of ND depend on viral pathotype, host factors, and environmental stressors, and may mimic other avian diseases such as avian influenza or infectious bronchitis, underscoring the need for laboratory confirmation (Banakar *et al*., 2016; Bello *et al*., 2018).

Despite the availability of effective vaccines, ND outbreaks continue to occur even in well-vaccinated flocks, largely due to improper vaccine handling, interference from concurrent infections, or exposure to field strains with antigenic variation (Absalón *et al*., 2019; Hu *et al*., 2022). Such outbreaks highlight gaps in vaccine-induced protection and the influence of secondary bacterial infections and management stressors on disease outcomes.

This case report describes a severe outbreak of ND in a flock of 9-week-old commercial cockerels that developed high morbidity and escalating mortality despite adherence to the recommended vaccination schedule, including a recent LaSota booster. The report provides insight into the interplay between NDV infection, potential vaccine failure, and concurrent bacterial involvement under intensive production conditions. The objective is to document the clinical presentation, gross and laboratory findings, and management response, thereby emphasizing the need for continuous field evaluation of vaccine efficacy, reinforcement of biosecurity practices, and timely veterinary intervention to mitigate ND losses.

CASE PRESENTATION/MATERIALS AND METHODS

Signalment, History, and Farm Observations

Six carcasses and three moribund birds were submitted to the Poultry Unit of the Senator Ali Modu Sherriff Ultra-Modern Veterinary Hospital (SAS-UVH), Maiduguri, Borno State, Nigeria, from a flock of 930 commercial cockerels aged nine weeks. The farmer reported a progressive increase in daily mortality over seven days, with cumulative losses exceeding 20% (approximately 186 birds) prior to submission. The flock was intensively managed under a deep-litter housing system (Plate 1a) with adequate space, ventilation, and routine biosecurity practices in place. Vaccination records indicated that the birds were current on all scheduled vaccines, including a Newcastle disease (ND) LaSota booster administered via drinking water one week before the onset of illness. No new stock introductions were made during this period, and feed was obtained from a reputable commercial source.

Clinically, affected birds exhibited marked somnolence, greenish-yellow diarrhea, anorexia, weakness, and respiratory distress typified by gasping and labored breathing. Feathers were ruffled and dull, and several birds were recumbent with drooping wings. Despite empirical treatment using NCO®, Neotreat®, and Virocine-K® through drinking water, mortality continued to escalate, prompting diagnostic investigation.

Diagnostic Approach

A systematic diagnostic plan was implemented to establish the etiology of the outbreak and identify potential complicating factors. Three moribund birds were examined clinically, while six freshly dead carcasses underwent post-mortem evaluation to document gross lesions characteristic of Newcastle disease or concurrent infections. A follow-up field visit was conducted to assess housing, management, and vaccination records.

Representative samples including whole blood, cloacal and oro-nasal swabs, and fecal materials were aseptically collected from both live and dead birds. Laboratory analyses included:

Serology: Detection of NDV antibodies using the haemagglutination inhibition (HI) test following standard OIE procedures.

Bacteriology: Isolation and identification of secondary bacterial pathogens by standard aerobic culture and biochemical methods, with antibiotic susceptibility testing performed using the Kirby-Bauer disc diffusion technique.

Coprology: Microscopic examination of fecal samples to rule out parasitic infections.

All diagnostic procedures followed institutional guidelines for animal welfare. Ethical clearance for the use of diagnostic samples was obtained from the Faculty of Veterinary Medicine Research Ethics Committee, University of Maiduguri (Ref: FVM/UNIMAID/2025/ETH-024).

The integrated diagnostic workflow enabled the confirmation of the primary infectious agent and assessment of secondary bacterial involvement contributing to the morbidity and mortality pattern observed within the flock.



Plate 1. Poultry pen showing sick birds off feed with drooped wings (a) and a clinically affected bird with ruffled feathers and greenish-yellow diarrhea (b)

RESULTS

Postmortem Findings

Gross examination of the submitted moribund birds revealed extensive multisystemic lesions consistent with infection by a virulent strain of Newcastle disease virus (NDV), complicated by secondary bacterial invasion. The respiratory, gastrointestinal, and circulatory systems were prominently affected, aligning with the reported signs of acute respiratory distress, depression, and profuse greenish diarrhea.

Skeletal and Cutaneous Lesions

Carcasses exhibited cyanosis of the comb and wattles (Plate 2a), with petechial to ecchymotic hemorrhages along the shanks (Plate 2b). These changes reflected vascular fragility and hypoxia typical of velogenic NDV. The skin appeared pale and dry, consistent with dehydration secondary to diarrhea and anorexia.

Respiratory Lesions

The nares and oral cavities contained mucopurulent exudates, while the trachea showed diffuse congestion, edema, and petechial hemorrhages (Plate 3a), indicating hemorrhagic tracheitis. The lungs were dark red, heavy, and oozed blood on section (Plate 3b), signifying severe congestion and pulmonary hemorrhage compatible with viral pneumonitis.

Digestive Lesions

The proventriculus showed petechial hemorrhages around glandular tips and openings (Plate 4a,b), pathognomonic of velogenic viscerotropic NDV. The intestines, particularly the ileocecal junction and cecal tonsils, displayed diffuse congestion and petechiae (Plate 5). Pinpoint hemorrhages extended to the serosal and peritoneal surfaces (Plate 6a,b), reflecting severe vascular injury.

Hepatic Lesions

The liver was enlarged, friable, and mottled with multifocal hemorrhages and subcapsular necrosis (Plate 7), indicating hepatocellular degeneration secondary to systemic viral insult and hypoxia.

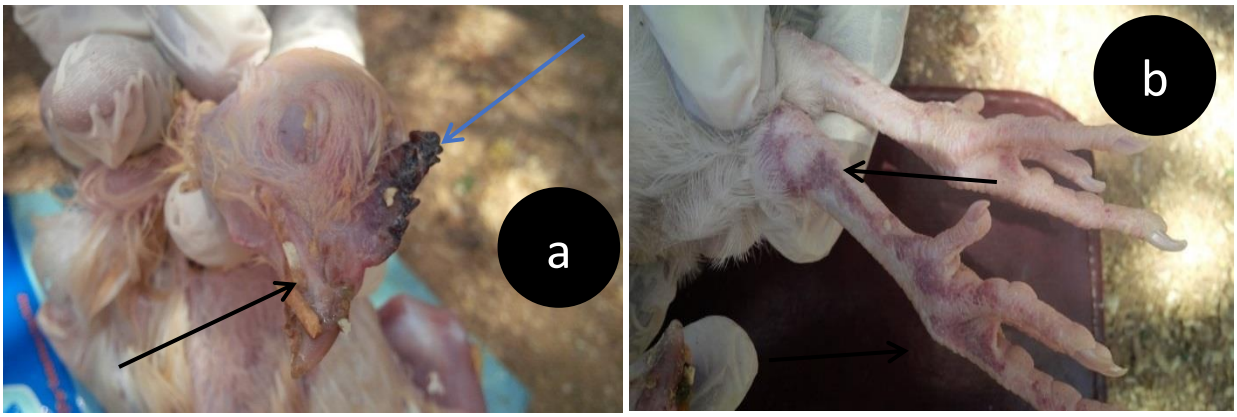

Plate 2. Carcass showing cyanotic comb and nasal discharge (blue and red arrows, respectively) (a); hemorrhages on shank (b)



Plate 3. Hemorrhagic tracheal mucosa (a); congested and hemorrhagic lungs (b).



Plate 4. Petechial hemorrhages on proventricular mucosa (a,b)



Plate 5. Hemorrhages at the ileocecal junction

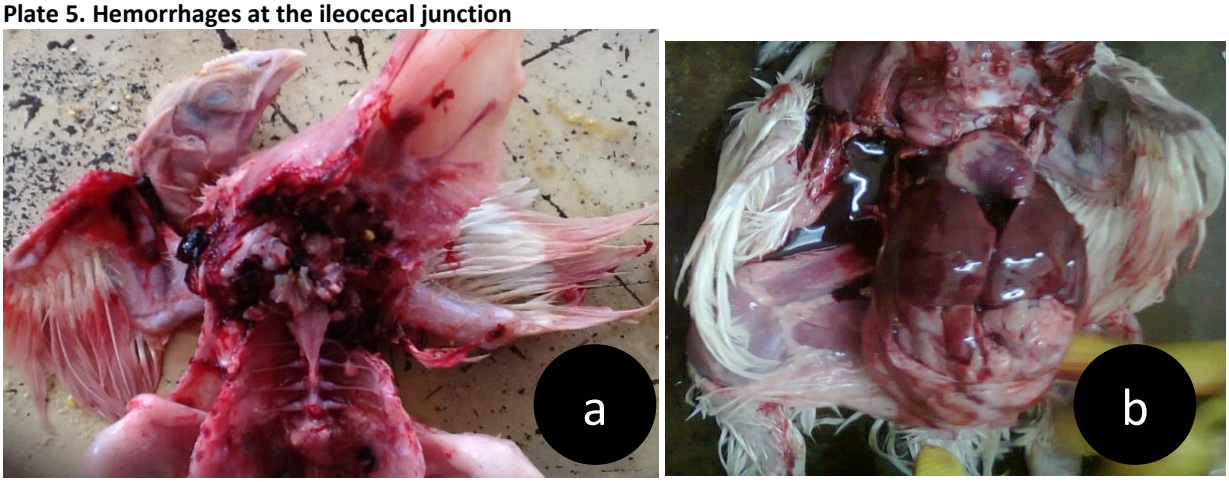

Plate 6. Congested peritoneal organs (a); petechial hemorrhages in peritoneal cavity (b)



Plate 7. Liver showing subcapsular necrosis

Differential Diagnoses

Based on the clinical presentation of acute onset depression, anorexia, respiratory distress, greenish diarrhea, and high mortality among the affected cockerels, several infectious diseases of poultry were initially considered. These included Highly Pathogenic Avian Influenza (HPAI), Infectious Bronchitis (IB), Fowl Cholera, and Velogenic Newcastle Disease (VND).

Highly Pathogenic Avian Influenza was considered because of its overlapping signs of cyanosis of comb and wattles, respiratory signs, and hemorrhages in visceral organs. However, the absence of edema of the head and face, lack of fibrinous pericarditis, and the pattern of hemorrhagic lesions particularly the petechial hemorrhages along the proventricular glandular tips favored Newcastle disease over HPAI.

Infectious Bronchitis was also considered due to the respiratory distress and tracheal congestion, but the pronounced systemic hemorrhages, enteric involvement, and neurological signs observed in some

birds were inconsistent with the typical presentation of IB.

Fowl Cholera was ruled out as no caseous exudates or focal necrosis were observed in the liver, which are characteristic of *Pasteurella multocida* infection. Similarly, there were no features suggestive of Infectious Laryngotracheitis or Avian Metapneumovirus infection.

Tentative Diagnosis

After considering and systematically excluding other potential causes, the constellation of clinical manifestations, vaccination history, and the characteristic gross lesions observed at necropsy strongly implicated a velogenic strain of Newcastle disease virus (NDV) as the primary etiologic agent. The extensive multisystemic hemorrhagic and necrotic changes particularly the petechial hemorrhages along the proventricular glandular tips, tracheal congestion with mucosal hemorrhages, cyanosis of comb and wattles, and disseminated vascular lesions are pathognomonic indicators of Velogenic Viscerotropic Newcastle Disease (VVND).

The concurrent presence of mucopurulent exudates within the upper airways, friable hepatomegaly, and pulmonary congestion further suggested secondary bacterial colonization, likely exacerbating the respiratory compromise and systemic deterioration. Collectively, these findings substantiated a tentative diagnosis of Velogenic Newcastle Disease complicated by secondary bacterial infections, consistent with the clinical presentation of acute respiratory and enteric distress observed in the affected cockerels.

Confirmatory Diagnosis Outcome

To accurately establish the etiological agent responsible for the outbreak and to identify potential concurrent infections, a range of diagnostic samples was systematically collected from clinically affected and apparently healthy cockerels. The sampling strategy was guided by observed clinical manifestations and differential diagnoses formulated during field investigation. All specimens were promptly submitted to the Virology Laboratory of the National Veterinary Research Institute (NVRI), Vom, Plateau State, as well as to the Veterinary Microbiology and Veterinary Parasitology Laboratories of the University of Maiduguri, Borno State, Nigeria, for diagnostic evaluation.

Serological Analysis

Whole blood samples were aseptically obtained via the brachial vein from both diseased and apparently healthy birds within the affected flock. The sera were separated and subjected to Hemagglutination Inhibition (HI) testing to detect antibodies specific to Newcastle disease virus (NDV) and assess the degree of seroconversion within the population.

Bacteriological Examination

To investigate potential secondary bacterial pathogens contributing to disease severity, oro-nasal and cloacal swabs were collected from clinically affected birds under aseptic conditions. The samples were cultured on both selective and non-selective media, including Blood agar, MacConkey agar, and Xylose Lysine Deoxycholate (XLD) agar, and incubated under optimal aerobic and microaerophilic conditions. Resultant bacterial isolates were subjected to Gram staining and a battery of biochemical identification tests to determine species identity. To further characterize the isolates, antimicrobial susceptibility testing was conducted using the Kirby–Bauer disk diffusion method on Mueller–Hinton agar, following Clinical and Laboratory Standards Institute (CLSI) guidelines.

Parasitological and Coprological Examination

To rule out parasitic co-infections as potential predisposing or compounding factors, fresh fecal samples were collected from affected birds for detailed parasitological analysis. The samples were examined using direct smear, flotation, and sedimentation techniques to detect the presence of helminth ova, larvae, and protozoan cysts.

Management: Electrolyte Replenishment

To correct dehydration and metabolic derangements resulting from diarrhea and inappetence, Vitalyte + Dextrose (Vitalflash®) was administered at 5 g per 4 L of drinking water for 5 days.

Immune Support

To enhance host resistance and modulate immune response, Nigella sativa–based herbal immunostimulants were incorporated into the regimen. The phytochemical constituents of this supplement have been shown to stimulate antibody production and augment antiviral defense mechanisms, thereby improving flock resilience.

Environmental and Biosecurity Management:

Strict biosecurity protocols were enforced to curtail viral dissemination and bacterial contamination. The flock was immediately isolated, and routine disinfection of drinkers, feeders, and the poultry environment was carried out daily using broad-spectrum disinfectants. Controlled access to the pen and restriction of visitor movement were also implemented to minimize mechanical transmission of the pathogen.

Results of Laboratory Diagnosis

Samples processed at the Virology Laboratory of the National Veterinary Research Institute (NVRI), Vom, Plateau State, Nigeria, and at the Departments of Veterinary Microbiology and Veterinary Parasitology

and Entomology Research Laboratories of the University of Maiduguri, Borno State, Nigeria revealed the following diagnostic findings as summarized as follows:

Serological Outcome

Haemagglutination inhibition (HI) test:

The HI assay demonstrated variable titers of Newcastle Disease Virus (NDV) antibodies among the tested sera. Clinically affected birds exhibited markedly higher antibody titers (geometric mean titer: 7.8 $\log_2$) compared to apparently healthy flock mates (geometric mean titer: 5.2 $\log_2$), signifying active seroconversion and ongoing viral infection within the flock.

Enzyme-linked immunosorbent assay (ELISA)

ELISA results corroborated the HI findings, revealing elevated NDV-specific antibody concentrations in the affected birds. Mean optical density (OD) values were significantly above the established positivity threshold, confirming NDV circulation and supporting the field diagnosis of Newcastle disease.

Bacteriological Examination

Culture and identification:

Bacteriological culture of oro-nasal and cloacal swabs yielded substantial growth of opportunistic bacterial pathogens, including *Escherichia coli* (45%, 9/20), *Salmonella* spp. (30%, 6/20), and *Pasteurella multocida* (15%, 3/20). No growth was observed in 10% (2/20) of the samples.

Antimicrobial susceptibility testing

Kirby–Bauer disk diffusion assays demonstrated high resistance of isolates to tetracycline and amoxicillin, whereas most were sensitive to gentamicin. These results guided the selection of therapeutic agents for field intervention.

Parasitological and Coprological Examination

Microscopic examination (flotation and sedimentation)

Fecal examinations revealed no detectable helminth eggs or coccidian oocysts in any of the tested samples (0/20; 100%), ruling out concurrent parasitic involvement in the outbreak.

Confirmatory diagnosis

Based on the combined serological, bacteriological, and field observations, Newcastle disease was confirmed as the primary etiological agent. The course of the disease was complicated by secondary bacterial infections involving *E. coli*, *Salmonella* spp., and *P. multocida*.

DISCUSSION

The present investigation reports an outbreak of Newcastle Disease (ND) among 9-week-old cockerels in Maiduguri, Borno State, Nigeria. The clinical, pathological, and laboratory findings collectively confirm infection with a virulent strain of Newcastle Disease Virus (NDV), highlighting the continuing threat this pathogen poses to poultry production in regions with limited biosecurity and variable vaccination efficiency (Amoia *et al*., 2021; Ipara *et al*., 2023).

The observed respiratory and neurological signs, coupled with classical postmortem lesions such as hemorrhagic tracheitis and proventricular petechiation, typify velogenic viscerotropic NDV infection. However, the rapid progression and high mortality despite reported vaccination suggest a probable vaccine break, reflecting either improper vaccine handling/administration, antigenic mismatch, or immune suppression due to concurrent infections. Similar field failures have been documented where circulating NDV genotypes differed antigenically from the vaccine strain or where immunosuppressive agents such as *Mycoplasma* spp. were present (Kapczynski *et al*., 2013; Martinez *et al*., 2018; Moustapha *et al*., 2023). The implications of vaccine failure in this region are significant. Poultry farmers often rely on live LaSota vaccines administered through drinking water, a practice vulnerable to uneven dosing and cold-chain interruptions. These factors, coupled with poor record-keeping and low farmer awareness, may contribute to reduced flock immunity and silent viral circulation. Hence, strengthening vaccine cold-chain maintenance, promoting trained personnel-led administration, and improving post-vaccination monitoring are essential to prevent similar outbreaks.

The detection of NDV in the presence of bacterial co-infections, as evidenced by the response to doxycycline and gentamicin, also highlights the likelihood of secondary infections that complicate disease outcomes. Such mixed infections may enhance viral pathogenicity and mortality while promoting antimicrobial misuse, a growing concern in regional poultry systems where antibiotics are routinely used as growth promoters (Gowthaman *et al*., 2019). These further stresses the need for integrated disease management emphasizing biosecurity, vaccination discipline, and rational antimicrobial use rather than reliance on therapeutic interventions.

The supportive management strategies applied electrolyte supplementation and herbal immunostimulation using *Nigella sativa* illustrate practical on-farm mitigation measures that may improve survival in the absence of specific antivirals. Although herbal immunomodulators show promise in enhancing host response, their role remains adjunctive and should not substitute for effective preventive biosecurity and vaccination programs (Salem *et al*., 2023).

Field assessment of the affected farm revealed lapses such as inadequate disinfection, contact with free-ranging birds, and poor quarantine of new stock. These reflect common biosecurity weaknesses in small-scale Nigerian poultry systems, which enable virus persistence and rapid farm-to-farm spread (OIE, 2022). Sustainable ND control, therefore, depends on context-specific interventions integrating farmer education, strict movement control, and regionally adapted vaccines.

CONCLUSION

This case report documents an outbreak of velogenic viscerotropic Newcastle Disease (vvND) in a flock of 9-week-old commercial cockerels in Maiduguri, Borno State, Nigeria. Diagnosis was established through field clinical observation, characteristic post-mortem lesions, and confirmatory laboratory tests, including serological assays (HI and ELISA), which demonstrated high NDV antibody titers. Bacteriological findings revealed secondary infections with *Escherichia coli*, *Salmonella* spp., and *Pasteurella multocida*, which exacerbated disease severity. The outbreak occurred despite prior LaSota vaccination, highlighting possible issues of vaccine handling, storage, or strain variation. Prompt institution of electrolyte therapy, immune support with *Nigella sativa*–based herbal immunostimulants, and strict biosecurity measures aided recovery and containment. This case emphasizes the continuing threat of vvND and the importance of vigilant surveillance and vaccination quality control in endemic areas.

To prevent recurrence of similar outbreaks, vaccination practices should be reinforced through proper handling, storage, and post-vaccination monitoring. Routine molecular surveillance of circulating NDV strains is advised to detect antigenic drift and inform vaccine updates. Strengthened farm biosecurity, controlled movement of personnel, and judicious antibiotic use guided by sensitivity testing remain essential components of effective ND control.

Conflict of Interest: Authors declare no conflict of interest in publishing this work.

REFERENCES

Absalón, A. E., Cortés-Espinosa, D. V., Lucio, E., Miller, P. J., & Afonso, C. L. (2019). Epidemiology, control, and prevention of Newcastle disease in endemic regions: Latin America. *Tropical Animal Health and Production, 51*(5), 1033–1048. https://doi.org/10.1007/s11250-019-01843-z

Al-Rasheed, M. (2024). A review of current knowledge on avian Newcastle infection in commercial poultry in the Kingdom of Saudi Arabia. *Open Veterinary Journal, 14*(1), 12–18. https://doi.org/10.5455/OVJ.2024.v14.i1.2

Amoia, C. F. A. N., Nnadi, P. A., Ezema, C., & Couacy-Hymann, E. (2021). Epidemiology of Newcastle disease in Africa with emphasis on Côte d'Ivoire: A review. *Veterinary World, 14*(7), 1727–1740. https://doi.org/10.14202/vetworld.2021.1727-1740

Bello, M. B., Yusoff, K., Ideris, A., Hair-Bejo, M., Peeters, B. P. H., & Omar, A. R. (2018). Diagnostic and vaccination approaches for Newcastle disease virus in poultry: The current and emerging perspectives. *BioMed Research International, 2018*, Article 7278459. https://doi.org/10.1155/2018/7278459

Desingu, P. A., Singh, S. D., Dhama, K., Vinodhkumar, O. R., Nagarajan, K., Singh, R., Malik, Y. S., & Singh, R. K. (2021). Pathotyping of Newcastle disease virus: A novel single *BsaHI* digestion method for detection and differentiation of avirulent and virulent strains. *Microbiology Spectrum, 9*(3), e0098921. https://doi.org/10.1128/spectrum.00989-21

Gowthaman, V., Singh, S. D., Dhama, K., Ramakrishnan, M. A., Malik, Y. P. S., Gopala Krishna Murthy, T. R., Chitra, R., & Munir, M. (2019). Co-infection of Newcastle disease virus genotype XIII with low pathogenic avian influenza exacerbates clinical outcome in vaccinated layer flocks. *VirusDisease, 30*(3), 441–452. https://doi.org/10.1007/s13337-019-00533-6

Hu, Z., He, X., Deng, J., Hu, J., & Liu, X. (2022). Current situation and future direction of Newcastle disease vaccines. *Veterinary Research, 53*, 99. https://doi.org/10.1186/s13567-022-01118-w

Ipara, B. O., Otieno, D. J., Nyikal, R. A., & Makokha, N. S. (2023). Farmers' awareness and perceptions on Newcastle disease in chicken: Evidence from high and low rainfall regions of Kenya. *Cogent Food & Agriculture, 10*(1), Article 2292869. https://doi.org/10.1080/23311932.2023.2292869

Jeong, J., Kim, Y., An, I., Wang, S. J., Kim, Y., Lee, H. J., Choi, K. S., Im, S. P., Min, W., Oem, J. K., & Jheong, W. (2018). Complete genome sequence of a novel avian paramyxovirus isolated from wild birds in South Korea. *Archives of Virology, 163*(1), 223–227. https://doi.org/10.1007/s00705-017-3588-6

Kalonda, A., Saasa, N., Kajihara, M., Nao, N., Moonga, L., Ndebe, J., Mori-Kajihara, A., Mukubesa, A. N., Sakoda, Y., Sawa, H., Takada, A., & Simulundu, E. (2024). Phylogenetic analysis of Newcastle disease virus isolated from poultry and wild waterfowl in Zambia. *Microorganisms, 12*(2), 354. https://doi.org/10.3390/microorganisms12020354

Kapczynski, D. R., Afonso, C. L., & Miller, P. J. (2013). Immune responses of poultry to Newcastle disease virus. *Developmental and Comparative Immunology, 41*(3), 447–453. https://doi.org/10.1016/j.dci.2013.04.012

Moustapha, A., Talaki, E., Akourki, A., & Ousseini, M. (2023). Newcastle disease virus in poultry: Current status and control prospects. *World Veterinary Journal, 13*(2), 240–249. https://doi.org/10.54203/scil.2023.wvj26

Nagy, A., Ali, A., Zain El-Abideen, M. A., Kilany, W., & Elsayed, M. (2020). Characterization and genetic analysis of emergent virulent Newcastle disease viruses in Egypt. *Transboundary and Emerging Diseases, 67*, 2000–2012. https://doi.org/10.1111/tbed.13543

World Organisation for Animal Health (WOAH). (2022). *Manual of diagnostic tests and vaccines for terrestrial animals (Terrestrial Manual 2022).* Retrieved from https://www.woah.org/en/what-we-do/standards/codes-and-manuals/terrestrial-manual-online-access