Sahel Journal of Life Sciences FUDMA (SAJOLS)
September 2026 Vol. 4(3): 216-224
ISSN: 3027-0456 (Print)
ISSN: 1595-5915 (Online)
DOI: *https://doi.org/10.33003/sajols-2026-0403-22*

Research Article

Histopathological Effects of Ethanol *Khaya grandifoliola* Leaf Extract on Reproductive Organs of Wistar Rats

***Olugbenga Onaolapo Afolabi[1], Akinola Adekunle Fowotade[1], Abdulrasaq Nuhu[1], Ahmed Bayo Opalekunde[1], Wasiu Olanrewaju Garuba[1], Solomon Adebayo Bernard[2], Oluwabunmi Iyadunni Akanbiola[2], and Seidat Omolabake Hassan[2]**

[1]Department of Medical Laboratory Science, Kwara State University, Nigeria
[2]Department of Histopathology and Morbid anatomy, University of Ilorin Teaching Hospital, Ilorin, Kwara State, Nigeria

****Corresponding Author's email*: afolabioo@uniilorin.edu.ng; Phone: +2348035010292**

ABSTRACT
*Khaya grandifoliola (*Meliaceae) is widely used in West African traditional medicine for reproductive health, but the reproductive safety of its leaf extract remains uncharacterized, unlike the documented toxicity of *Khaya senegalensis* stem bark. This study evaluated the histopathological effects of ethanol *Khaya grandifoliola* leaf extract on the testes, ovaries, and uterus of adult Wistar rats. Thirty-two rats (16 male, 16 female) were divided into four groups of eight: a negative control receiving distilled water and three groups receiving 100, 200, or 500mg/kg/day of extract orally for 28 days. Phytochemical screening confirmed limonoids, flavonoids, tannins, saponins, alkaloids, and anthraquinones, with flavonoids (13.79%) and alkaloids (10.2%) most abundant. Body weight, organ weight, organ coefficient, and haematoxylin and eosin-stained sections were evaluated at the end of treatment. Seminiferous tubules and Leydig cells, ovarian follicular architecture, and uterine myometrial/endometrial architecture remained intact at all doses, with no necrosis, haemorrhage, architectural collapse, or cellular atypia. Findings in the ovaries and uterus were comparable between treated and control animals, consistent with normal physiological variation. One-way ANOVA revealed no significant between-group differences in body weight, organ weight or coefficient, testicular morphometry, uterine histology scores, or ovarian follicle count. These results indicate that ethanol *Khaya grandifoliola* leaf extract did not induce structural damage to reproductive organs even at the highest dose tested (500 mg/kg/day for 28 days), suggesting that the reported toxicity of Khaya may be specific to the plant part rather than a genus-wide property.

Keywords: Ethanol leaf extract; Histopathology; *Khaya grandifoliola*; Organ coefficient; Reproductive toxicity; Safety evaluation; Wistar rats

Citation: Afolabi, O.O., Fowotade, A.A., Nuhu, A., Opalekunde, A.B., Garuba, W.O., Bernard, S.A., Akanbiola, O.I., & Hassan, S.O. (2026). Histopathological Effects of Ethanol *Khaya grandifoliola* Leaf Extract on Reproductive Organs of Wistar Rats. *Sahel Journal of Life Sciences FUDMA*, 4(3): 216-224. DOI: *https://doi.org/10.33003/sajols-2026-0403-22*

INTRODUCTION

Khaya grandifoliola (Meliaceae), popularly known as African mahogany, is a medicinal plant native to West Africa, with Nigeria a key area of its distribution; decoctions or infusions of the leaves are used traditionally to treat infertility, menstrual disorders, erectile dysfunction, malaria, diabetes, and inflammatory conditions (Mukaila *et al*., 2021). Traditional medicine continues to hold considerable value as a source of treatment in many African countries, including Nigeria, owing to its accessibility and affordability (World Health Organization [WHO],

2019). The plant's pharmacological activities have been attributed mainly to its limonoid, flavonoid, alkaloid, terpenoid, and saponin content, conferring antimalarial, antioxidant, and anti-inflammatory properties, but these same bioactive constituents can also be toxic to rapidly dividing cells and tissues with high hormonal activity (Olatunji *et al*., 2021).

Despite this wide traditional application in treating fertility problems, no systematic investigation of the reproductive safety of *Khaya grandifoliola* leaf extract has been carried out; a recently published comprehensive review of the plant's pharmacology and toxicology notes that reproductive toxicity data for the leaves remain far less extensive than the documented stem-bark toxicity data available for the closely related species *Khaya senegalensis* (Mukaila *et al*., 2021). This gap is of direct public-health relevance: reproductive organ dysfunction, whether environmental, nutritional, or pharmacologically induced in origin, is already a substantial problem in Sub-Saharan Africa, where the frequency of infertility is estimated at about 17% (Gedef *et al*., 2025), and the use of herbal remedies, such as *Khaya grandifoliola* leaf preparations, that are not properly studied and lack standardized dosing regimens can compound this burden rather than relieve it (Awodele *et al*., 2014). It was this combination of wide traditional use, an unquantified safety profile, and a substantial background burden of reproductive dysfunction that motivated the present evaluation.

Histopathological investigation (haematoxylin and eosin staining) continues to play a major role in reproductive toxicology, allowing identification of possible toxic effects through the assessment of organ damage (Suvarna *et al*., 2020). Wistar rats are considered one of the most suitable models for such research, given their physiological similarity to humans and their genetically homogeneous population (Krubaa & Yogitha, 2024). Several studies report adverse reproductive effects of other plants within the same family (Meliaceae); for example, the leaf extract of Azadirachta indica has been shown to disrupt reproductive parameters in male rats (Cardoso *et al*., 2025). Similar pharmacological properties among plants of the same family therefore do not guarantee reproductive safety of a different species or its individual plant parts, which is the specific gap this study addresses for *Khaya grandifoliola* leaf extract.

This study therefore investigated the histopathological effects of ethanol *Khaya grandifoliola* leaf extract on the testes, ovaries, and uterus of adult Wistar rats exposed to oral doses of 100, 200, or 500 mg/kg/day for 28 days, a dose range informed by the sub-acute toxicity doses previously established for the stem bark of the related species *Khaya anthotheca* (Akwongo *et al*., 2025) and by the fertility-relevant dosing used in *Khaya senegalensis* stem-bark studies (Wireko *et al*., 2024), with the aim of providing an evidence-based safety evaluation of the plant and a starting point for further assessment by regulatory authorities.

MATERIALS AND METHODS

Study Design and Area

A laboratory-based comparative experimental study design was chosen to conduct this study at the Department of Medical Laboratory Science, Faculty of Allied Health Sciences, Kwara State University, Malete, Kwara State, Nigeria. Duration of the experiment was 8 weeks (2 weeks of adaptation, 4 weeks (28 days) of treatment and subsequent tissue preparation and analysis).

Experimental Animals

Thirty-two healthy, adult, nulliparous, non-pregnant Wistar rats (*Rattus norvegicus*; 16 male, 16 female) were obtained from a certified breeding centre and acclimatized for 14 days under a 12-hour light-dark cycle with standard food and water available ad libitum. Rats were allocated into four groups of eight (n = 8 per group; four males and four females per group) so that effects on both male-specific (testicular) and female-specific (ovarian and uterine) reproductive organs could be assessed within the same dose groups (Tortora & Derrickson, 2021). Because testicular, ovarian, and uterine endpoints are sex-specific, each organ was analyzed separately by sex across the four dose groups (n = 4 per sex per group); one-way ANOVA was used to compare the male sub-groups on testicular parameters and, independently, the female sub-groups on ovarian and uterine parameters. Body weight and weight gain, which were recorded for all animals, were likewise compared within sex.

Ethical Considerations

This study was ethically approved by the Ministry of Livestock Development, Kwara State Government (LSKW/2005/1/95) and was conducted in accordance with the NIH Guide for the Care and Use of Laboratory Animals (National Institutes of Health [NIH], 2020) and the ARRIVE 2.0 guidelines (Percie du Sert *et al*., 2020). Inclusion criteria were healthy adult Wistar rats aged 10–12 weeks and weighing 150–180 g, confirmed healthy on physical examination; animals with any health issue or confirmed pregnancy were excluded.

Plant Material and Extract Preparation

Fresh *Khaya grandifoliola* leaves were collected from a bush in Oke Oyi, Ilorin, Kwara State, and authenticated at the Herbarium of the Department of Plant Biology, Faculty of Life Sciences, University of Ilorin (herbarium voucher number UILH/001/1650/2026). The plant material was washed, air-dried for two weeks, and ground into a fine powder using a mechanical grinder. Five hundred grams of the powder was macerated for 72 hours in 2 litres of 70% ethanol under intermittent agitation, filtered through Whatman No. 1 filter paper, then concentrated under reduced pressure at 50°C using a rotary evaporator, and stored in a hermetic container at 4°C until further use (Mukaila *et al*., 2021).

Phytochemical Screening

Preliminary qualitative and quantitative phytochemical screening of the ethanol *Khaya grandifoliola* leaf extract used in this study was carried out conventionally on the extract batch itself, at the Department of Medical Laboratory Science, Faculty of Allied Health Sciences, University of Ilorin, Ilorin, Kwara State, Nigeria, using standard reagent-based methods (Harborne, 1998; Sofowora, 1993). The extract was screened for alkaloids using Mayer's test, flavonoids using the Shinoda test, tannins using the ferric chloride test, saponins using the froth test, anthraquinones using the Borntrager's test, and limonoids using the Salkowski test; reducing sugars were screened using Fehling's test. Constituents confirmed present were graded qualitatively ("+" = present, "++" = strongly present), and flavonoids, tannins, saponins, alkaloids, and anthraquinones were further quantified gravimetrically and expressed as a percentage of the dried extract weight; limonoids and sugars were confirmed present by the colour and precipitation reactions above but were not carried forward to gravimetric quantification (Table 1).

Experimental Grouping and Dose Administration

Each dose of the extract was suspended in distilled water according to each animal's body weight and administered orally once daily for 28 days as follows: Group NCK, 0.2 mL distilled water; Group K100, 100 mg/kg/day of the extract; Group K200, 200 mg/kg/day of the extract; Group K500, 500 mg/kg/day of the extract. This dose range was selected based on the sub-acute toxicity dose range previously used for methanolic stem-bark extract of the closely related species *Khaya anthotheca*, at which treatment-related effects were observable without mortality (Akwongo *et al*., 2025), and was further informed by the fertility-relevant dosing used in ethanolic *Khaya senegalensis* stem-bark studies (Wireko *et al*., 2024). Feed and water were available to the animals throughout the experiment.

On day 29, after an overnight fast, animals were euthanized by diethyl ether inhalation. The oestrous cycle stage of the female rats was not monitored or controlled for prior to euthanasia; because ovarian follicular populations and uterine epithelial height and morphology vary across the oestrous cycle, this is acknowledged as a source of baseline variance in the female histological endpoints and is discussed further below. Testes, ovaries, and uterus were dissected and washed in normal saline. These organs were fixed in 10% neutral buffered formalin for 48 hours, dehydrated in a graded ethanol series (70–100%), cleared in xylene, embedded in molten paraffin wax, cut into 3–5 µm sections using a rotary microtome, floated on a water bath at 45°C, and mounted on frosted-end slides.

Histopathological Staining and Microscopic Assessment

Tissue sections were stained using the conventional haematoxylin and eosin (H&E) method: deparaffinization in xylene; rehydration through descending grades of ethanol; staining with Harris' haematoxylin for 5 minutes; differentiation in 1% acid alcohol for 10 seconds; bluing in Scott's tap water substitute for 2 minutes; counterstaining with eosin for 2 minutes; dehydration through ascending grades of ethanol; clearing in xylene; and mounting in DPX mounting medium under a coverslip (Suvarna *et al*., 2020). Stained slides were examined using a compound digital light microscope at ×100, ×200, and ×400 magnification. The testes were assessed for seminiferous tubule degeneration, Leydig cell hyperplasia, and decreased spermatogenesis, and scored for spermatogenic stage on a 3-point scale (1 = early-stage, 2 = mixed-stage, 3 = late-stage spermatogenesis), alongside tubule diameter and epithelial height measurements. The ovaries were assessed for follicular atresia, cystic change, and corpus luteal abnormalities, with corpus luteal, antral, Graafian, primary, secondary, and atretic follicles enumerated per group. The uterus was assessed for endometrial epithelial alterations, apoptotic-type epithelial change, and stromal inflammation, each scored semi-quantitatively using a 4-point epithelial height scale (1 = low cuboidal to 4 = tall columnar), a 4-point apoptosis scale (0 = none to 3 = marked), and a 4-point inflammation scale (0 = none to 3 = marked). Representative fields were photographed at ×400 magnification.

Data Analysis

All data were analyzed using SPSS software (SPSS Inc., Chicago, IL, USA), version 23.0. Body weight and weight-gain data were compared within sex across the four dose groups; testicular parameters were compared among the male sub-groups (n = 4 per group) and ovarian and uterine parameters among the female sub-groups (n = 4 per group), each using one-way ANOVA, with statistical significance set at $p < 0.05$. Data from the histopathological study were described and illustrated with representative photomicrographs showing differences between the control and experimental groups.

RESULTS

The four experimental groups comprised a negative control treated with distilled water and three experimental groups administered 100 (K100), 200 (K200), or 500 (K500) mg/kg/day of ethanol Khaya grandifoliola leaf extract for 28 consecutive days. Qualitative and quantitative phytochemical screening of the extract batch used in this study, carried out as described in Materials and Methods, confirmed the presence of limonoids, flavonoids, tannins, saponins, alkaloids, anthraquinones, and sugars; among the constituents quantified, flavonoids were the most abundant (13.79%), followed by alkaloids (10.2%), tannins (3.00%), saponins (0.82%), and anthraquinones (0.31%), while limonoids and sugars were confirmed present but not quantified (Table 1). These findings are broadly consistent with the phytochemical classes previously reported for Khaya grandifoliola leaf extract in the literature (Mukaila *et al*., 2021; Olatunji *et al*., 2021).

Ovarian sections from all groups showed preserved follicular architecture, with corpus luteal, antral, and atretic follicles identified in every group, including the negative control; primary follicles were present in the negative control and K500 only, secondary follicles in K100, K200, and K500, and Graafian follicles in K200 and K500 only (Figure 1; Table 3). Atretic follicles were prominent across all groups, including the negative control, consistent with normal ovarian turnover rather than an extract-specific effect. Corpus luteal and primary follicle counts were highest in the K500 group, while K200 and K500 shared the highest secondary follicle count and K200 had the higher of the two Graafian follicle counts (Table 3).

Table 1: Phytochemical Constituents of *Khaya grandifoliola* Ethanol Leaf Extract

Phytochemical constituent	Qualitative	Quantitative (%)
Flavonoids	++	13.79
Tannins	+	3.00
Saponins	+	0.82
Alkaloids	+	10.2
Limonoids	+	–
Anthraquinones	+	0.31

+ = present; ++ = strongly present; – = confirmed present but not quantified.

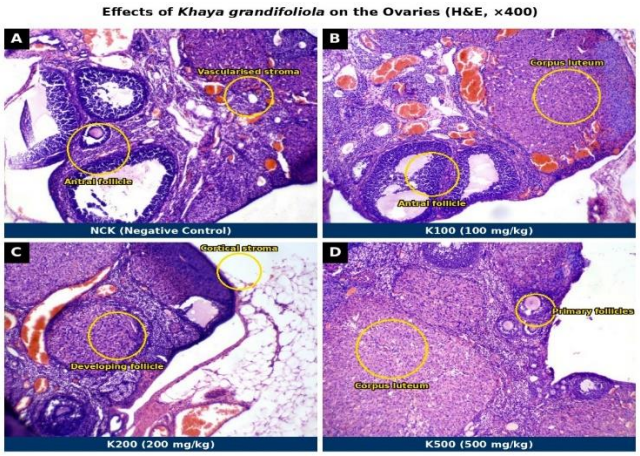

Figure 1: Photomicrographs of the effects of *Khaya grandifoliola* on the Ovaries (H&E, ×400)

H&E = haematoxylin and eosin. (A) NCK (negative control): antral follicle and vascularised stroma. (B) K100: corpus luteum and antral follicle. (C) K200: developing follicle and cortical stroma. (D) K500: corpus luteum and primary follicles. Follicular and luteal architecture is preserved in all groups, with no evidence of necrosis or haemorrhage.

Uterine sections showed preserved myometrial and endometrial tissue in all groups, with epithelial height ranging from tall columnar (NCK, K100) to low columnar (K200) and columnar (K500), and variable degenerative epithelial cell counts and stromal inflammation that did not track consistently with dose (Figure 2; Table 2). Scores assigned using the rubric described in Materials and Methods showed the negative control and K500 groups returning comparable epithelial height and inflammation scores, while K100 tied with K500 for the highest epithelial height score and scored highest for apoptosis, and K200 scored the lowest across all three parameters, including the lowest inflammation score (Table 2).

Testicular sections across all groups showed closely packed seminiferous tubules with normal interstitial Leydig cells and no features of injury or cellular atypia (Figure 3). Spermatogenic staging varied: K100 showed predominantly early-stage spermatogenesis, while K200 and K500 showed predominantly late-stage spermatogenesis with abundant elongating and elongated spermatids; morphometric scores (spermatogenic score, tubule diameter, epithelial height) were consistent with this staging.

Final body weight, weight gain, and testes, ovary, and uterus weights were broadly similar across all groups, and organ coefficients were likewise similar for the testes and ovaries, with a marginally lower uterine coefficient in K200. One-way ANOVA confirmed no statistically significant between-group differences across all 17 structural, weight, and coefficient parameters examined ($p > 0.05$ for all comparisons; Table 4). No histopathological changes indicative of structural toxicity, such as necrosis, haemorrhage, architectural collapse, tubular degeneration, or cellular atypia, were observed in the testes, ovaries, or uterus at any dose (100–500 mg/kg/day), corroborated by unchanged organ weights and normal body weight gain across all groups, indicating no evidence of systemic toxicity.

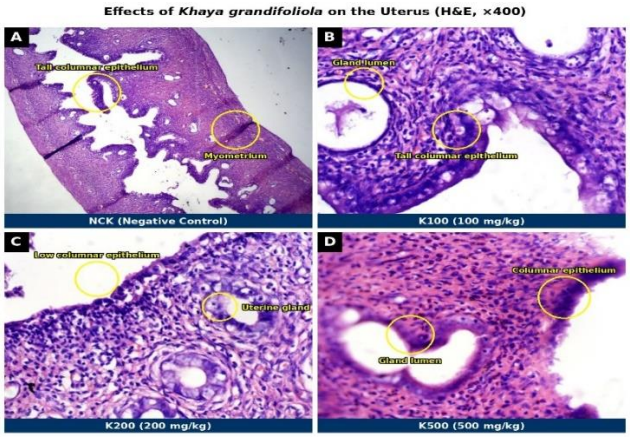

Figure 2: Photomicrographs of the effects of *Khaya grandifoliola* on the Uterus (H&E, ×400)

H&E = haematoxylin and eosin. (A) NCK (negative control): tall columnar epithelium and myometrium. (B) K100: gland lumen and tall columnar epithelium. (C) K200: low columnar epithelium and uterine gland. (D) K500: gland lumen and columnar epithelium. Myometrial and endometrial architecture is preserved in all groups, with no necrosis, glandular atrophy, or squamous metaplasia.

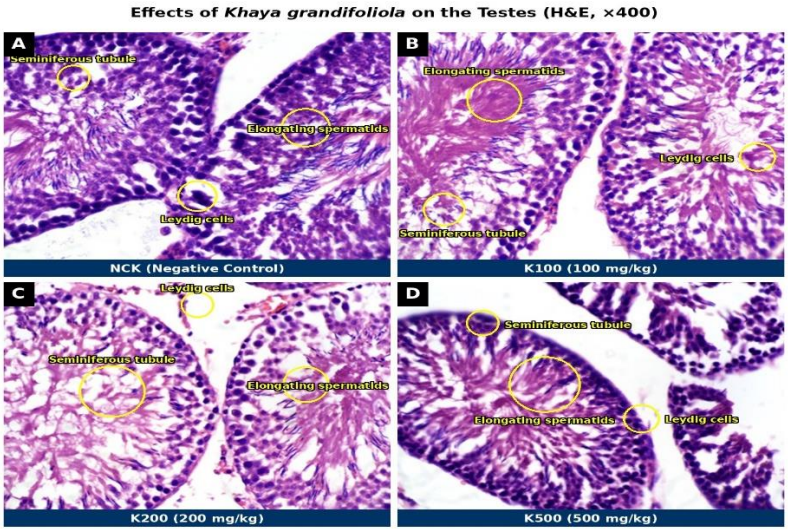

Figure 3: Photomicrographs of the effects of *Khaya grandifoliola* on the testis (H&E, ×400)

H&E = haematoxylin and eosin. (A) NCK (negative control): seminiferous tubule, elongating spermatids, and Leydig cells. (B) K100: elongating spermatids, Leydig cells, and seminiferous tubule. (C) K200: seminiferous tubule, Leydig cells, and elongating spermatids. (D) K500: seminiferous tubule, elongating spermatids, and Leydig cells. Seminiferous epithelial organisation and Leydig cell morphology are preserved in all groups, with no degenerative changes.

Table 2: Uterine Histopathological Scores across the Four Experimental Groups (NCK, K100, K200, K500)

Group	Epithelial Height Score (1–4)	Apoptosis Score (0–3)	Inflammation Score (0–3)
NCK	3	2	2
K100	4	3	1
K200	2	1	0
K500	4	1	2

Scores are semi-quantitative group values assigned according to the scoring rubric defined in Materials and Methods (Histopathological Staining and Microscopic Assessment).

Table 3: Ovarian Follicle Population across the Four Experimental Groups (NCK, K100, K200, K500)

Group	Corpus Luteum	Antral Follicles	Graafian Follicles	Primary Follicles	Secondary Follicles	Atretic Follicles
NCK	4	4	0	7	0	7
K100	7	4	0	0	1	13
K200	5	1	2	0	5	5
K500	16	6	1	12	5	5

Values represent total follicle counts identified per group across the examined ovarian sections; individual per-animal counts and standard deviations were not separately recorded in the underlying dataset.

Table 4: One-Way ANOVA Comparing Body Weight, Organ Weight, and Histopathological Parameters Across the Four Experimental Groups (NCK, K100, K200, K500)

Parameter	F-statistic	p-value
Final body weight	0.62	0.64
Weight gain	0.89	0.52
Testes weight	0.67	0.61
Ovaries weight	0.92	0.51
Uterus weight	1.03	0.47
Spermatogenic score	0.54	0.68
Tubule diameter	0.78	0.56
Testicular epithelial height	0.99	0.48
Uterine epithelium score	1.10	0.47
Uterine apoptosis score	1.56	0.37
Uterine inflammation score	0.75	0.59
Corpus luteum count	1.02	0.47
Antral follicle count	0.34	0.80
Graafian follicle count	1.20	0.42
Primary follicle count	1.33	0.38
Secondary follicle count	1.10	0.45
Atretic follicle count	0.88	0.52

ANOVA = analysis of variance. All 17 parameters compared across the four dose groups were not statistically significant ($p > 0.05$).

DISCUSSION

This study assessed the histopathological effects of ethanol Khaya grandifoliola leaf extract on the testes, ovaries, and uterus of adult Wistar rats. No feature associated with structural toxicity was observed at any dose examined. The ovarian findings merit particular care, since atretic follicles are often read as evidence of toxicity by themselves, in the current study corpus luteal, antral, and atretic follicles were identified in every group, including the negative control with primary, secondary, and Graafian follicles present only in specific dose groups (Table 3) and atretic counts in the negative control comparable to, or higher than, several treated groups. This fits established ovarian physiology, in which follicular atresia is the dominant fate of ovarian follicles under normal conditions, eliminating most follicles before ovulation (Xi *et al*., 2025), through a continuously operating apoptotic process in the granulosa cell layer rather than as a marker of exogenous insult (Chesnokov *et al*., 2024). The elevated corpus luteal and primary follicle counts in the highest-dose group likely reflect individual variability, possibly linked to oestrous cycle stage at euthanasia, which was not controlled for in this study, consistent with the absence of any statistically significant between-group difference in follicle counts.

This absence of ovarian and testicular change contrasts with reports on stem-bark preparations from the closely related species *Khaya senegalensis*, where ethanolic stem-bark extract in male Wistar rats produced mild-to-moderate spermatogonial degeneration and seminiferous tubule hyalinization from 100 mg/kg/day, worsening up to 1000 mg/kg/day (Wireko *et al*., 2024). The present study, using a comparable dose range but leaf rather than stem-bark material, did not observe comparable damage at any dose. *Khaya anthotheca* similarly showed dose-dependent gastric and hepatic toxicity from its stem-bark extract while leaving the heart and kidney unremarkable (Akwongo *et al*., 2025), indicating that toxicity within this genus is not uniform across organs. Together, these comparisons support a plant-part-specific, rather than genus-wide, interpretation of Khaya toxicity, consistent with the sparse reproductive toxicity data available specifically for *Khaya grandifoliola* leaf (Mukaila *et al*., 2021).

The testicular findings offer the clearest evidence against reproductive toxicity, with Leydig cell integrity and normal seminiferous epithelial organisation preserved at every dose; Leydig cells are the principal site of testosterone biosynthesis, so their preservation is necessary for normal androgen-dependent physiology. This is consistent with the wider literature on flavonoids structurally related to those in *Khaya grandifoliola*: quercetin protects testicular architecture against oxidative and chemically induced injury through antioxidant, anti-inflammatory, and anti-apoptotic mechanisms (Zhang *et al*., 2023), reducing oxidative and apoptotic

damage to testicular tissue in rats under metabolic stress (Tvrdá *et al*., 2022), offering a plausible explanation for the absence of testicular damage here. The uterine findings were more variable: epithelial height, degenerative epithelial cell counts, and stromal inflammation varied between animals within the same group without tracking consistently with dose, and the negative control showed changes comparable to, or exceeding, several treated groups (Table 2). Because oestrous cycle stage at euthanasia was not recorded or controlled for, this variability cannot be confidently separated from natural cycle-related change; nonetheless, the complete absence of necrosis, glandular atrophy, or squamous metaplasia in any group is a meaningful reassurance.

Final body weight, organ weights, and organ coefficients showed no statistically significant between-group differences, consistent with the unremarkable histopathology; the organ coefficient is a sensitive general indicator of target-organ effect, capable of detecting a treatment-related change before it appears on routine histopathology (Ballesteros-Ramírez *et al*., 2024), and current OECD guidance treats body weight, organ weight, and histopathology as complementary endpoints best interpreted jointly (Organisation for Economic Co-operation and Development [OECD], 2025). A recurring feature across every parameter was the absence of a clear, monotonic dose-response relationship across the 100–500 mg/kg/day range, this most plausibly reflects a genuine absence of toxic effect within the tested range. Hormonal and functional endpoints were not measured in the present study, and oestrous cycle stage was not controlled for at euthanasia; these results are therefore best read as a preliminary, hypothesis-generating safety signal rather than a definitive characterisation of the reproductive safety of ethanol Khaya grandifoliola leaf extract.

These findings carry direct translational relevance for how *Khaya grandifoliola* leaf preparations are actually used. Traditional decoctions and infusions are administered without standardized dosing, and the absence of structural reproductive toxicity up to 500 mg/kg/day, roughly the range previously associated with detectable, though still non-monotonic, treatment-related change in the related species *Khaya senegalensis* (Wireko *et al*., 2024), suggests a reasonable margin of structural safety at exposure levels consistent with customary use, while still leaving open the possibility that functional or hormonal effects could occur at doses below the structural threshold examined here. The absence of a monotonic dose-response relationship across the 100–500 mg/kg/day range, evident across the ovarian, uterine, and testicular endpoints alike, should not be read simply as an absence of a real effect; complex herbal mixtures containing multiple bioactive constituents, several of which (flavonoids, alkaloids, tannins) can behave differently at different concentrations, are increasingly recognized as candidates for hormetic or threshold-type dose-response curves, in which a genuine biological effect emerges only once a compound-specific threshold is exceeded, or reverses direction, rather than scaling continuously with dose. Distinguishing a true hormetic or threshold effect from simple biological noise would require a narrower, more closely spaced dose range and functional or biochemical endpoints capable of detecting sub-structural change, neither of which this study was designed to resolve; this distinction should be treated as a specific priority for the mechanistic follow-up work called for below, rather than as a settled conclusion from the present structural dataset.

CONCLUSION

Ethanol *Khaya grandifoliola* leaf extract, administered orally at doses up to 500 mg/kg/day for 28 days, produced no structural toxicity to the testes, ovaries, or uterus of adult Wistar rats, in contrast to the toxicity reported for stem-bark preparations of the related species *Khaya senegalensis,* indicating that Khaya toxicity is plant-part-specific rather than genus-wide. This structural safety signal is preliminary: it rests on histological and gross weight endpoints in a modest number of animals per sex.

Authors' Contributions: OOA was responsible for the study conceptualization, methodology, and hands-on animal handling and dosing. SAB and OIA carried out the tissue processing and staining. AAF provided overall project supervision, methodology, and administrative resources. HSO performed the data curation, formal statistical analysis, and manuscript writing (review and editing). All authors read and approved the final version of the manuscript. All authors read and approved the final manuscript.

Conflicts of Interest

The authors declare no conflict of interest.

Funding

The research did not receive any specific grant from funding agencies in the public, commercial or non-profit sectors.

Data Availability

Data supporting the findings of this study are available from the corresponding author upon reasonable request.

REFERENCES

Akwongo, B., Kakudidi, E. K., Nsubuga, A. M., Andama, M., Namaganda, M., Tugume, P., *et al*. (2025). Acute and sub-acute toxicity assessment of methanolic stem bark extract of *Khaya anthotheca* (Meliaceae) in Wistar rats. *Tropical Medicine and Health*, 53, 120.

Awodele, O., Amagon, K., Wannang, N., & Aguiyi, J. (2014). Traditional medicine policy and regulation in Nigeria: An index of herbal medicine safety. *Current Drug Safety*, 9(1), 16–22.

Ballesteros-Ramírez, R., Lasso, P., Urueña, C., Saturno, J., & Fiorentino, S. (2024). Assessment of acute and chronic toxicity in Wistar rats (Rattus norvegicus) and New Zealand rabbits (Oryctolagus cuniculus) of an enriched polyphenol extract obtained from Caesalpinia spinosa. *Journal of Toxicology*, 2024, Article 3769933.

Cardoso, C. A., Parca, A. V., Facciotti, P. R., Machado, L. C., Oliveira, V. C., Severi-Aguiar, G. D. C., & Martins, D. S. (2025). Natural pesticide, Azadirachta indica A. Juss. (Neem), disrupted reproductive parameters of male rats. *Journal of Ethnopharmacology*, 337, Article 118927.

Chesnokov, M. S., Mamedova, A. R., Zhivotovsky, B., & Kopeina, G. S. (2024). A matter of new life and cell death: Programmed cell death in the mammalian ovary. *Journal of Biomedical Science*, 31(1), 31.

Gedef, G. M., Taye, E. B., Mohammed, O. Y., Abegaz, M. Y., Asratie, M. H., & Andualem, F. (2025). Prevalence of infertility and its risk factors in Sub-Saharan Africa: A systematic review and meta-analysis. *Contraception and Reproductive Medicine*, 10, 73.

Harborne, J. B. (1998). Phytochemical methods: A guide to modern techniques of plant analysis (3rd ed.). Chapman & Hall.

Krubaa, P., & Yogitha, P. S. (2024). Albino Wistar rats: Advantages and limitations in biomedical research. *SBV Journal of Basic, Clinical and Applied Health Science*, 2(2), 61–65.

Mukaila, Y. O., Ajao, A. A.-N., & Moteetee, A. N. (2021). *Khaya grandifoliola* C. DC. (Meliaceae: Sapindales): Ethnobotany, phytochemistry, pharmacological properties, and toxicology. *Journal of Ethnopharmacology*, 278, Article 114253.

National Institutes of Health. (2020). *Guide for the care and use of laboratory animals* (8th ed.). National Academies Press.

Olatunji, T. L., Odebunmi, C. A., & Adetunji, A. E. (2021). Biological activities of limonoids in the genus *Khaya* (Meliaceae): A review. *Future Journal of Pharmaceutical Sciences*, 7, 74.

Organisation for Economic Co-operation and Development. (2025). *Test No. 407: Repeated dose 28-day oral toxicity study in rodents*. OECD Guidelines for the Testing of Chemicals, Section 4. OECD Publishing.

Percie du Sert, N., Hurst, V., Ahluwalia, A., Alam, S., Avey, M. T., and Baker, M. (2020). The ARRIVE guidelines 2.0: Updated guidelines for reporting animal research. *PLOS Biology*, 18(7), Article e3000410.

Sofowora, A. (1993). Medicinal plants and traditional medicine in Africa (2nd ed.). Spectrum Books.

Suvarna, S. K., Layton, C., & Bancroft, J. D. (2020). *Bancroft's theory and practice of histological techniques* (8th ed.). Elsevier.

Tortora, G. J., & Derrickson, B. H. (2021). *Principles of anatomy and physiology* (16th ed.). Wiley.

Tvrdá, E., Kováč, J., Ferenczyová, K., Kaločayová, B., Ďuračka, M., Benko, F., Almášiová, V., & Barteková, M. (2022). Quercetin ameliorates testicular damage in Zucker diabetic fatty rats through its antioxidant, anti-inflammatory and anti-apoptotic properties. *International Journal of Molecular Sciences*, 23(24), Article 16056.

Wireko, M. B., Sallah, L., Coffie, P. N., Asiwu, R. Y., Ananni-Akollor, M. E., and Titiloye, N. A. (2024). The effects of ethanolic stem-bark extract of *Khaya senegalensis* on fertility parameters and hormones on male Wistar rat. *Natural Product Communications*, 19(12), Article 1934578X241298104.

World Health Organization. (2019). *WHO global report on traditional and complementary medicine 2019*. World Health Organization.

Xi, H., Chen, X., Wang, X., Jiang, F., & Niu, D. (2025). Role of programmed cell death in mammalian ovarian follicular atresia. *Journal of Steroid Biochemistry and Molecular Biology*, 247, Article 106667.

Zhang, X., Tang, Y., Lu, G., & Gu, J. (2023). Pharmacological activity of flavonoid quercetin and its therapeutic potential in testicular injury. *Nutrients*, 15(9), Article 2231.